

ROLE OF IMAGING IN THE PROGNOSTICATION OF OUTCOME FOLLOWING TBI

- CT:

MARSHALL CLASSIFICATION
ROTTERDAM SCORE

- Basal cisterns
 - 0: normal
 - 1: compressed
 - 2: absent
- Midline shift
 - 0: no shift or ≤ 5 mm
 - 1: shift > 5 mm
- Epidural mass lesion
 - 0: present
 - 1: absent
- Intraventricular blood or traumatic SAH
 - 0: absent
 - 1: present

Mortality at six months increases with the score:

- score 1: 0%
- score 2: 7%
- score 3: 16%
- score 4: 26%
- score 5: 53%
- score 6: 61%

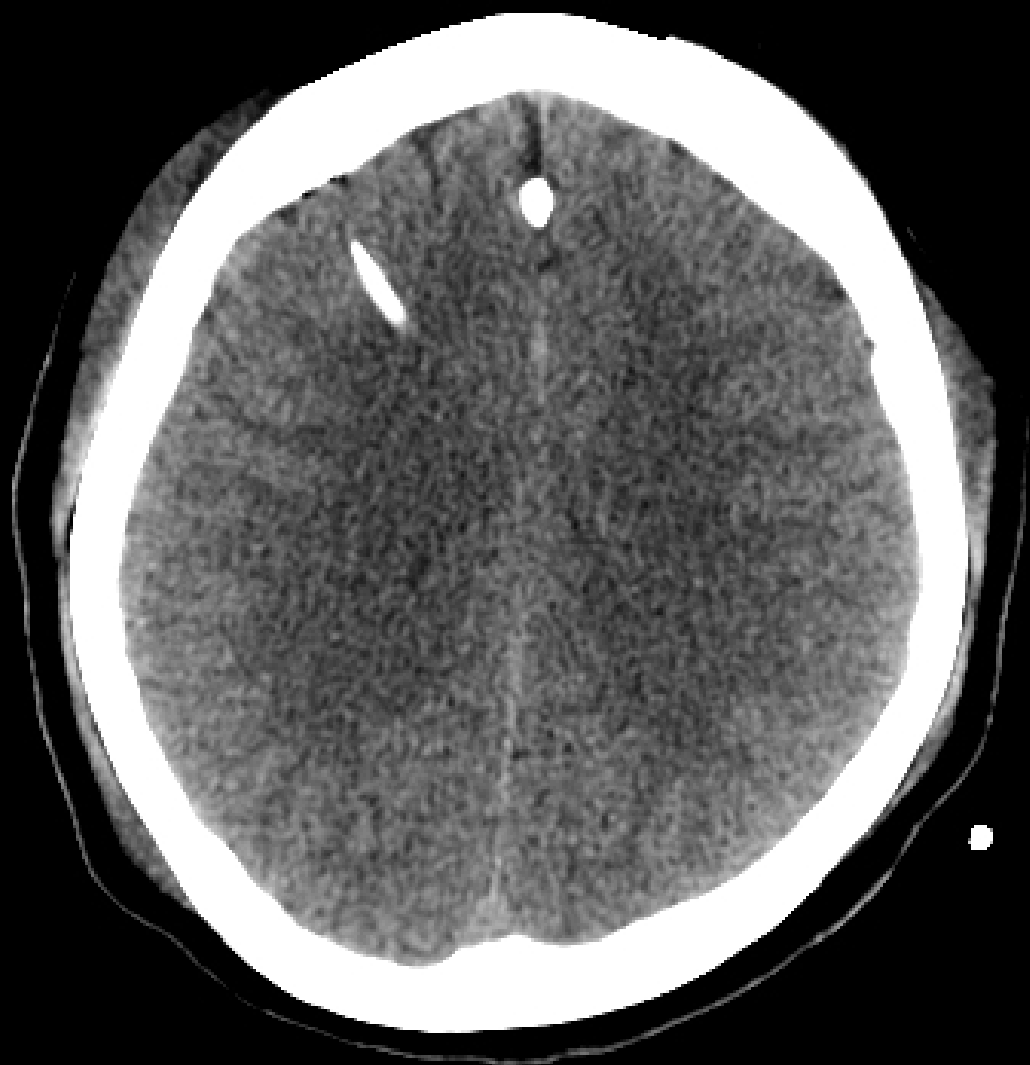MRI:

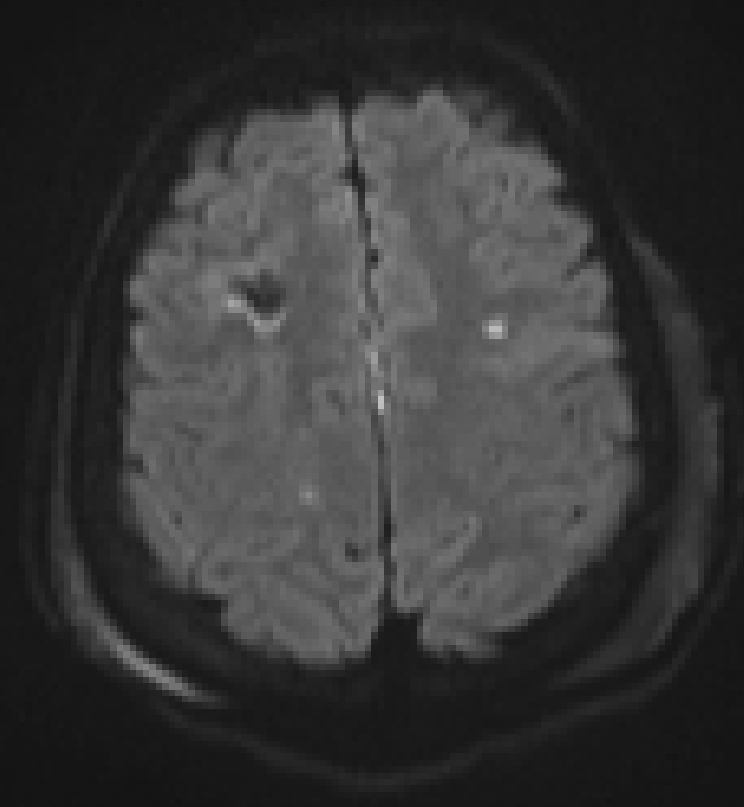
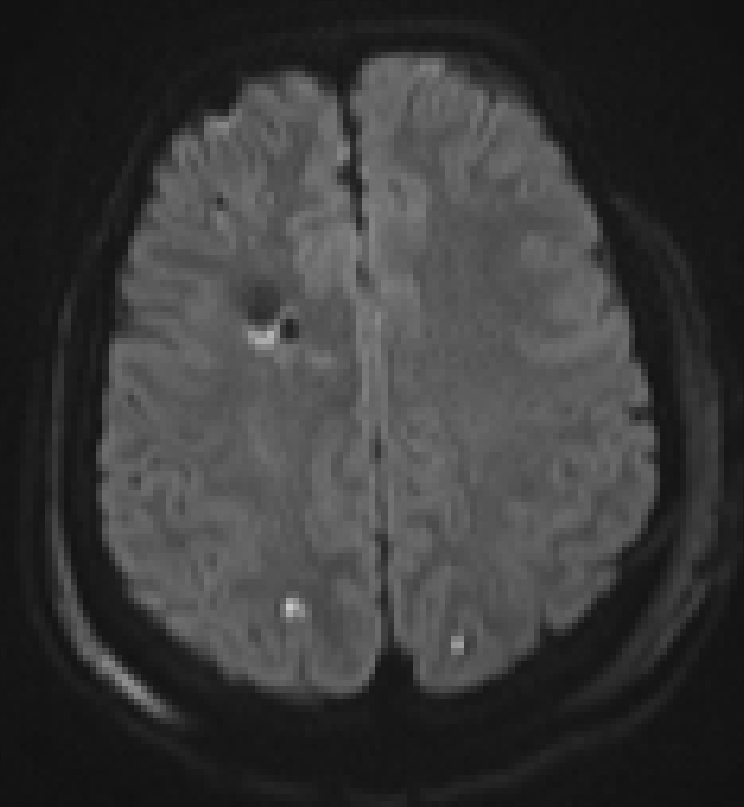
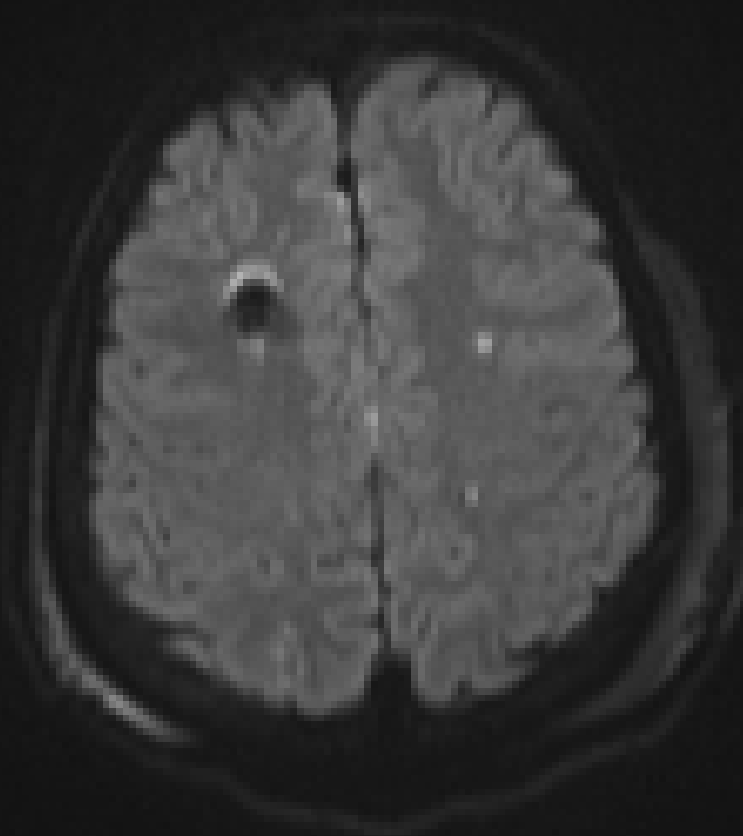
Detection of Traumatic Axonal injury (Diffuse Axonal Injury):

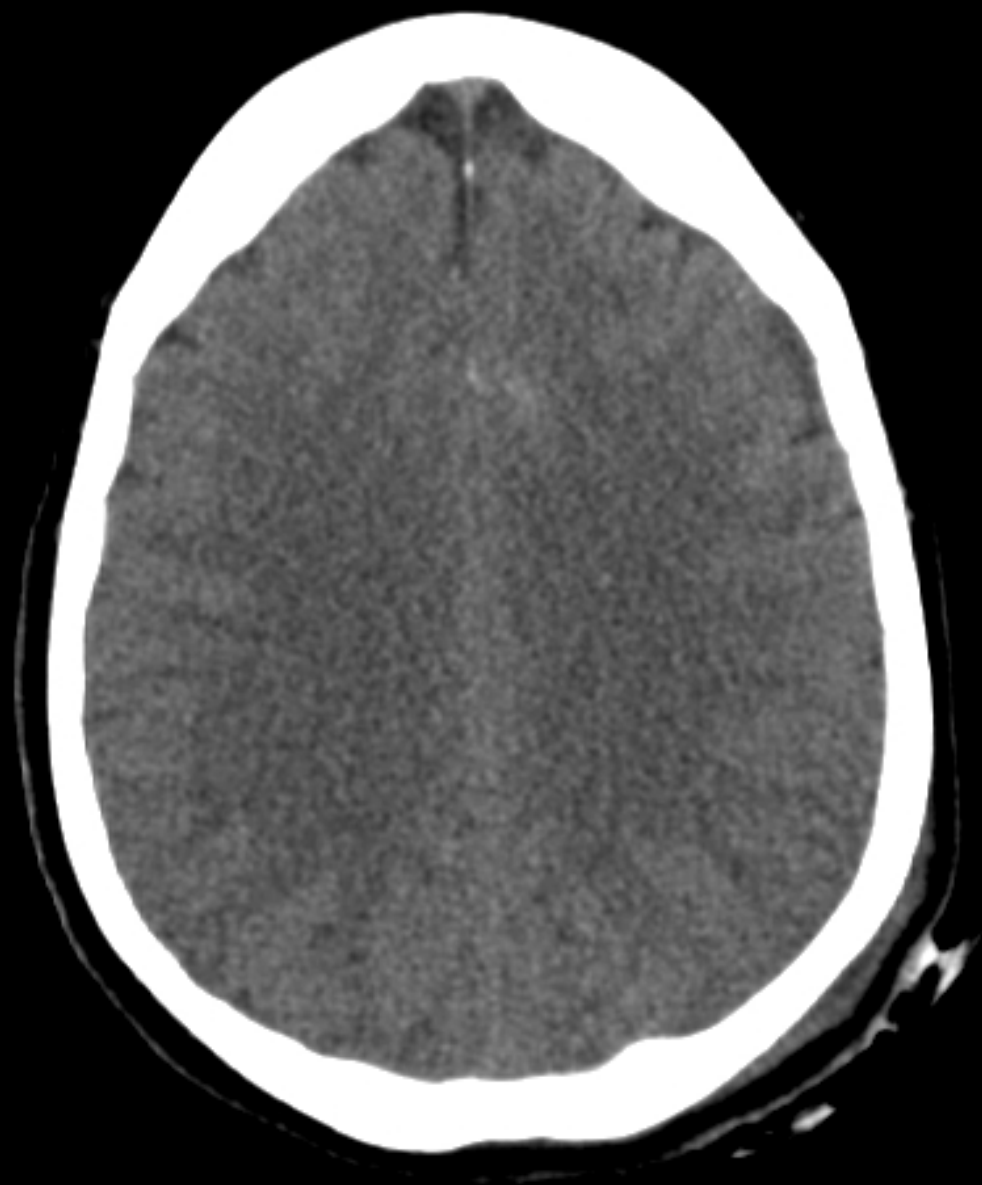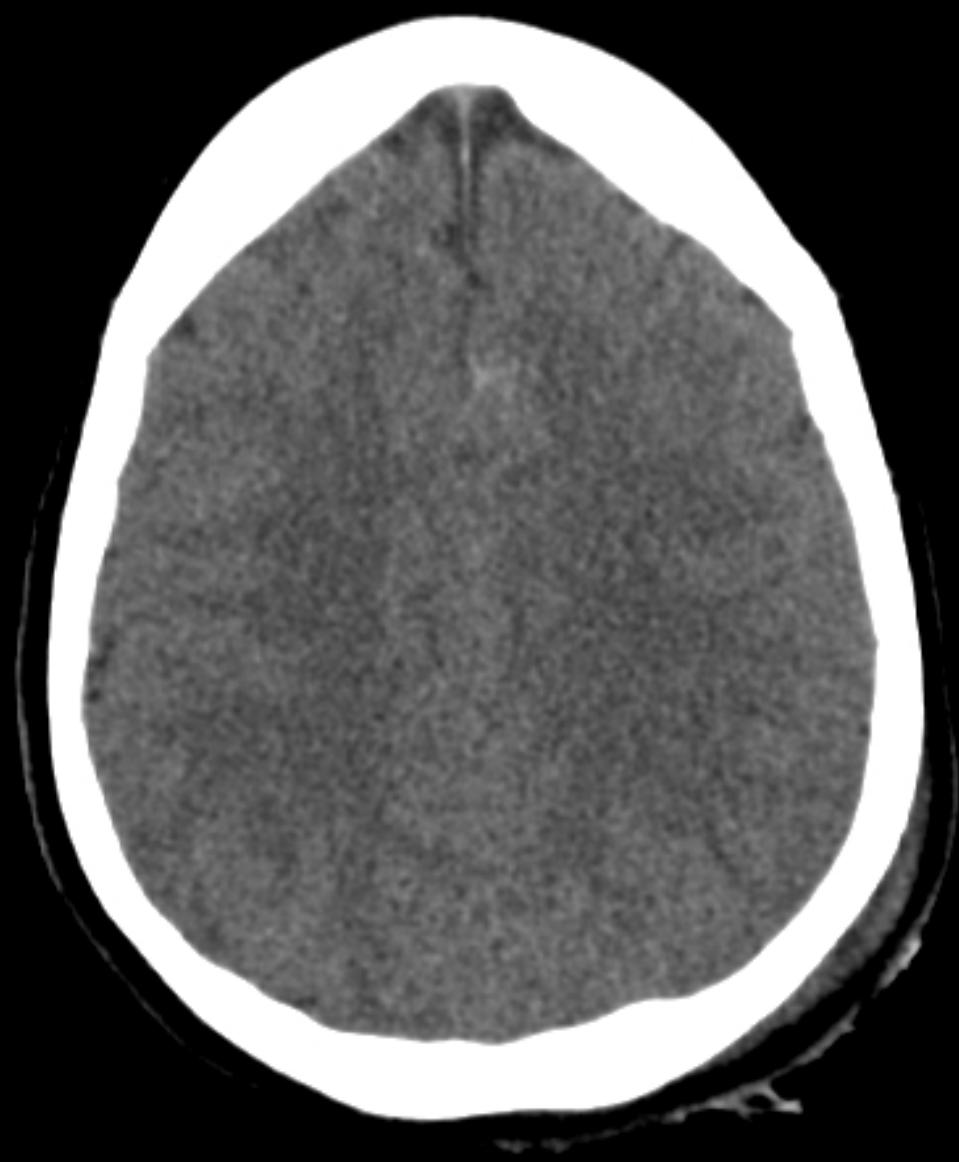Shear injury ('stretching injury') resulting from rapid deceleration.

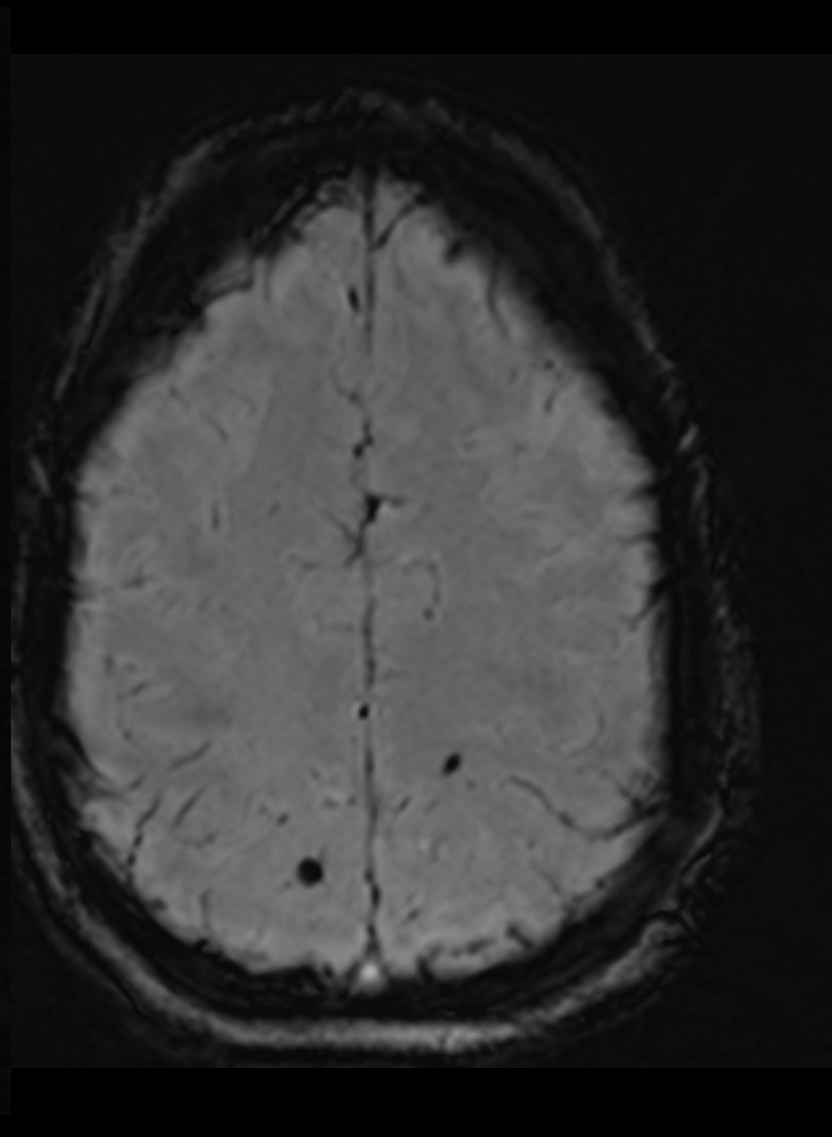
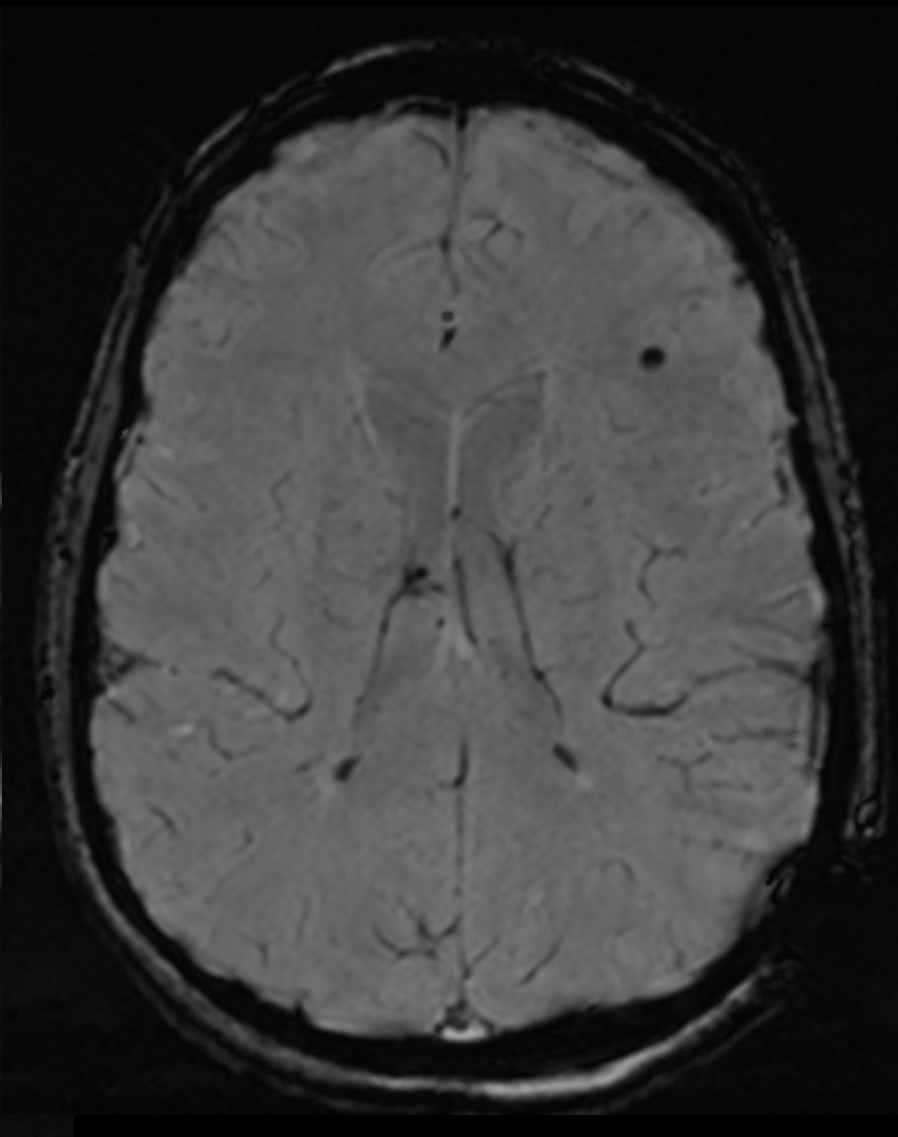
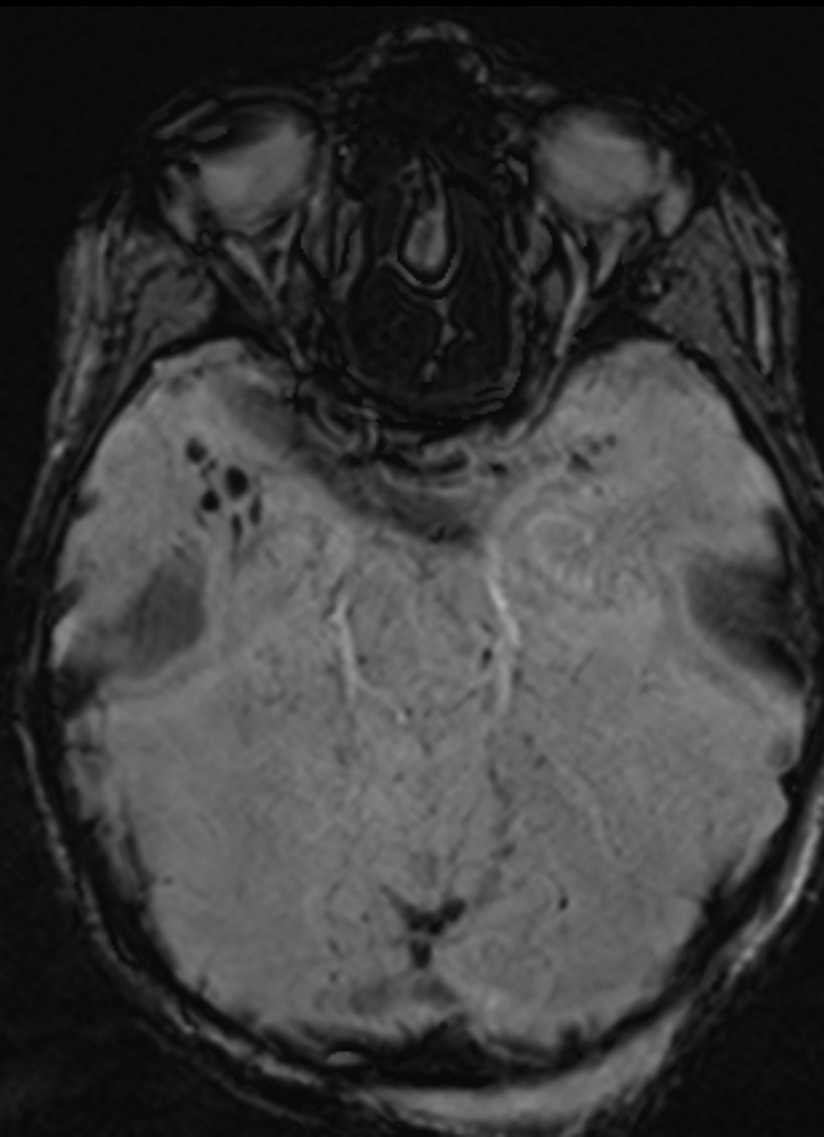
Classified:

- Stage 1: Superficial white matter. (Frontal and temporal lobe Grey white junction lesions)
- Stage 2: Lesions in deep white matter and corpus callosum (moderate TBI)
- Stage 3: Lesions in the brainstem (severe TBI)



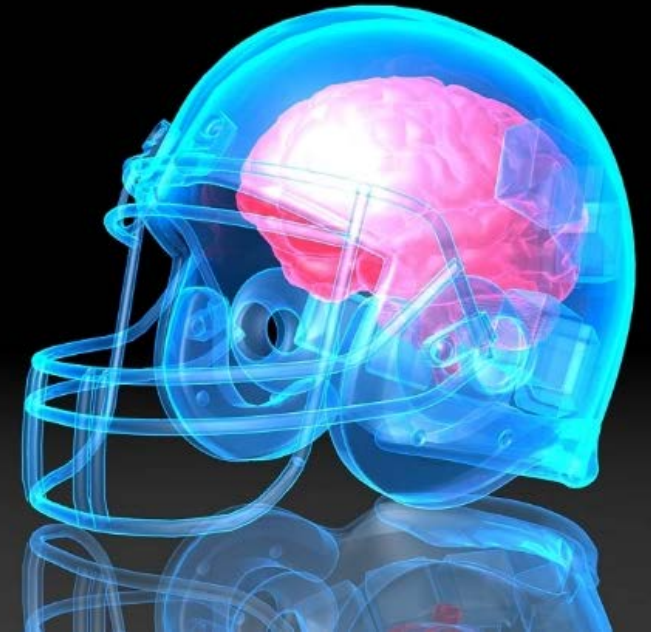






CHRONIC TRAUMATIC ENCEPHALOPATHY

- Neurodegenerative disease traditionally reported in boxers and football players who have sustained multiple episodes of *minor traumatic brain injury (mTBI)*
- mTBI ('**CONCUSSION**):
 - ❖ Glasgow Coma Scale score of 13 or higher at the time of injury.
 - ❖ Posttraumatic amnesia of less than 24 hours
 - ❖ Loss of consciousness for less than 30 minutes
 - ❖ Transient neurologic defects or disorientation at the time of injury



This Issue

Views **145,174** | Citations **1** | Altmetric **3388**

Original Investigation

July 25, 2017

Clinicopathological Evaluation of Chronic Traumatic Encephalopathy in Players of American Football

Jesse Mez, MD, MS^{1,2}; Daniel H. Daneshvar, MD, PhD^{1,3}; Patrick T. Kiernan, BA^{1,2}; [et al](#)

» [Author Affiliations](#)

JAMA. 2017;318(4):360-370. doi:10.1001/jama.2017.8334



Editorial
Comment



Related
Articles



Author
Interview



Multimedia

Key Points

Question What are the neuropathological and clinical features of a case series of deceased players of American football neuropathologically diagnosed as having chronic traumatic encephalopathy (CTE)?



Down
PDF



Cite



You May Also

Opinion

Advances and
Chronic Trau
Pugilists to A
July 25, 2017

Research

Assessment of

W I L L S M I T H

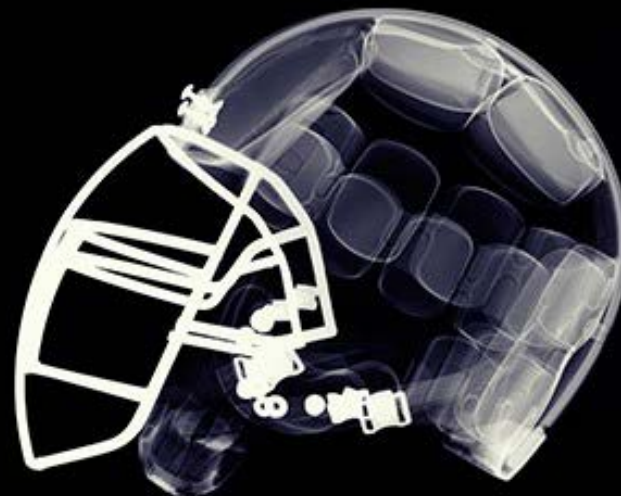


BASED ON A TRUE STORY.

C O N C U S S I O N

HE WILL STOP AT NOTHING TO EXPOSE THE TRUTH.

CLUMBIUM PICTURES presents a Columbia Pictures production WILL SMITH CONCUSSION AN ANDREW COHEN PRODUCTION A JAMES HANCOCK FILM WILL SMITH CONCUSSION A JAMES HANCOCK FILM WILL SMITH CONCUSSION A JAMES HANCOCK FILM
"CONCUSSION" WILL SMITH CONCUSSION WILL SMITH CONCUSSION WILL SMITH CONCUSSION WILL SMITH CONCUSSION WILL SMITH CONCUSSION WILL SMITH CONCUSSION WILL SMITH CONCUSSION
"WILL SMITH CONCUSSION" WILL SMITH CONCUSSION WILL SMITH CONCUSSION WILL SMITH CONCUSSION WILL SMITH CONCUSSION WILL SMITH CONCUSSION WILL SMITH CONCUSSION
"WILL SMITH CONCUSSION" WILL SMITH CONCUSSION WILL SMITH CONCUSSION WILL SMITH CONCUSSION WILL SMITH CONCUSSION WILL SMITH CONCUSSION WILL SMITH CONCUSSION
© 2015 Columbia Pictures Industries, Inc. All Rights Reserved. WillSmith.com CONCUSSION WILL SMITH CONCUSSION WILL SMITH CONCUSSION WILL SMITH CONCUSSION
SONY PICTURES Home Entertainment
COMING SOON



LEAGUE OF DENIAL

The NFL's Concussion Crisis

FRONTLINE

Tuesday, October 8, 2013

The NFL's
VIEW on
CONCUSSIONS

